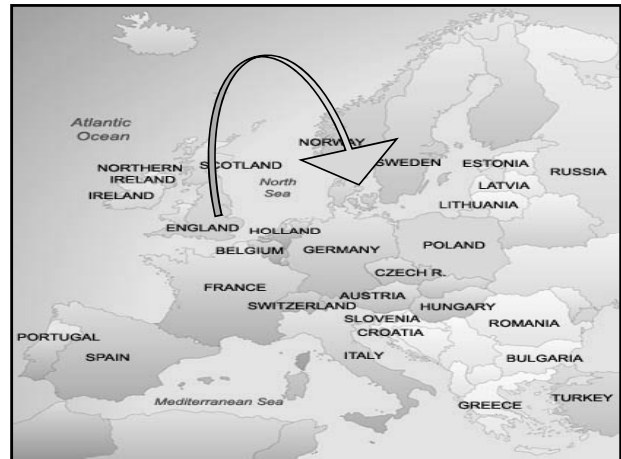


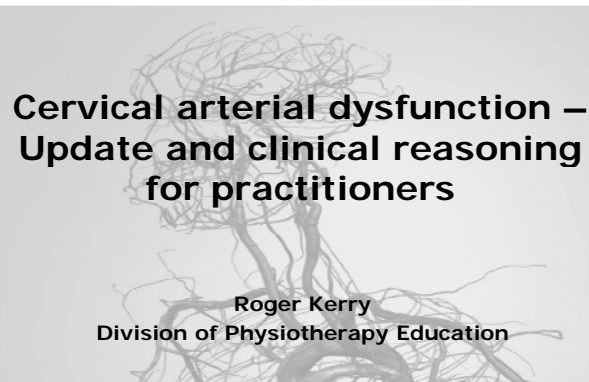


The University of Nottingham

Cervical arterial dysfunction – Update and clinical reasoning for practitioners


Roger Kerry
Division of Physiotherapy Education




FOREST

Cervical Arterial Dysfunction and Manual Therapy


Manual Therapy and Adverse Neurovascular Events: What's The Story..?




Four small black and white photographs arranged in a 2x2 grid, showing manual therapy techniques being performed on a patient's neck. The top-left photo shows a therapist's hands on the patient's neck. The top-right photo shows a therapist's hands on the patient's neck. The bottom-left photo shows a therapist's hands on the patient's neck. The bottom-right photo shows a therapist's hands on the patient's neck.



45-year-old male:
 - Headache +dizzy on lying down and rolling in bed;
 - Spinning of room lasting only seconds
 - Nausea+++;
 - no aural symptoms
 Health - fine




59-year-old male:
 - Headache, neck pain ("unusual") 2/12
 - "Falling to side / unsteady" without known cause
 - admitted A&E and discharged after 1/7
 - dizziness improved rapidly
 Health - CABG 2002




33-year-old female:
 Whiplash
 - Headache and neck pain with exacerbations;
 - Face pains;
 - Dizziness in crowds;
 - Veering in gait
 Health - fine

All "Simpsons" images: www.thesimpsons.com



42 year old male:
 - Neck pain (to jaw) / headache (side) 1/12
 - History of migraines but "not had this type of pain before";
 - Thinks he "pulled muscle" in throat because has difficulty swallowing food/drink.
 Health -High BP; been doing "McKenzie" neck exercises = worsening.



72-year-old female:
 - Headache, neck pain and stiffness; unsteady, 'drunken' gait
 - Dizziness on quick head turning
 - Reduced hearing right ear
 Health - hypertension, hypercholesterolaemia





All "Simpsons" images: www.thesimpsons.com

Cervical Arterial Dysfunction and Manual Therapy


"State of the Science"

Mis-interpretation of unreliable and incomplete data...


Guidelines

	MPA / APA 2006
	MTSC / CPA 2005
	NZMPA / NSP 2004
	Guidelines

Cervical Arterial Dysfunction and Manual Therapy

	Denmark
Guidelines ??	

Cervical Arterial Dysfunction and Manual Therapy

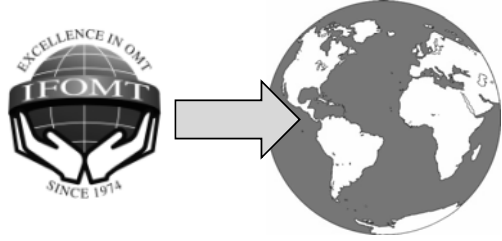
	UK
Guidelines	
MACP 2009	
Cervical Arterial Dysfunction and Manipulative Therapy INFORMATION DOCUMENT	

Cervical Arterial Dysfunction and Manual Therapy

Summary of International opinion (Guidelines)

- Focus on manipulation
- Focus on VBI
- Focus of physical tests
- Focus on medico-legal implications
- Agreement on paucity of evidence
- Attempt to estimate “size” of risk

IFOMT International Standard for screening the cervical region prior to Orthopaedic Manipulative Physiotherapy (OMT) intervention



The IFOMT logo features a globe with the text 'EXCELLENCE IN OMT' at the top, 'IFOMT' in the center, and 'SINCE 1974' at the bottom. A large arrow points from the logo to a separate globe showing the world map.



Cervical Arterial Dysfunction and Manual Therapy

Summary of literature (MT)

- “Size” of risk not possible to estimate
- Utility of test not good
- VBI difficult, or impossible, to predict

Cervical Arterial Dysfunction and Manual Therapy

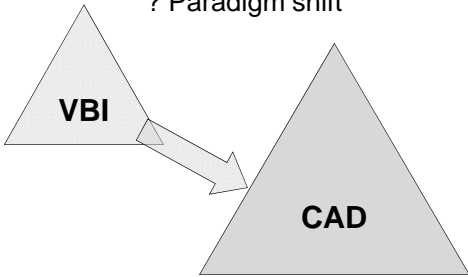
Summary of literature (non-MT)

- Good information on pathophysiology of neuro-vascular events of cervical vessels
- Good information on predictors to stroke (VA and ICA)

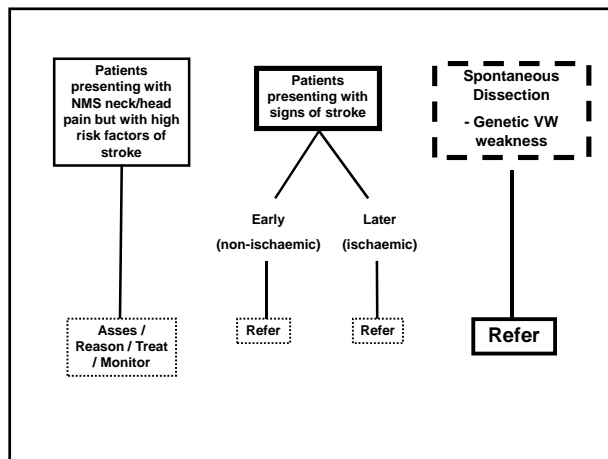
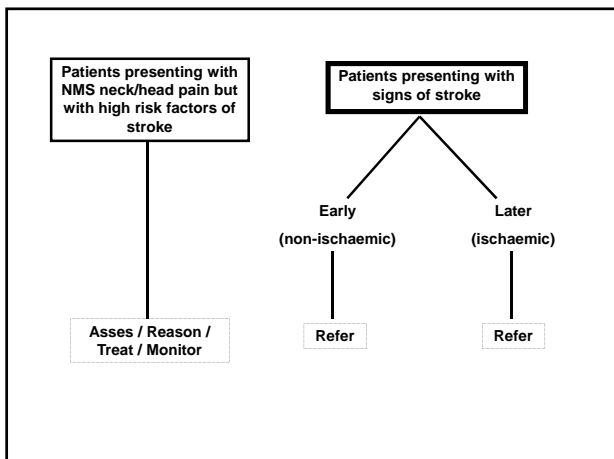
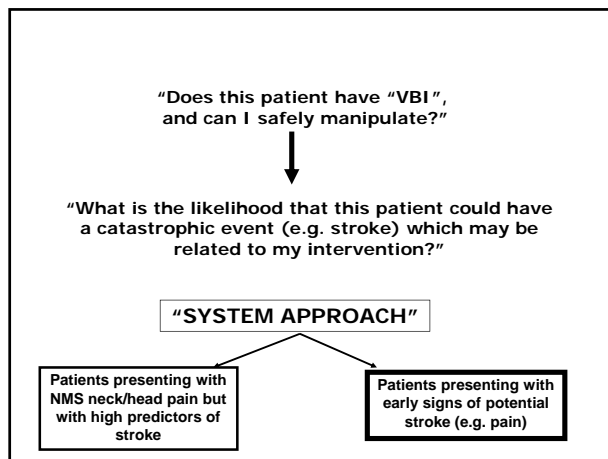
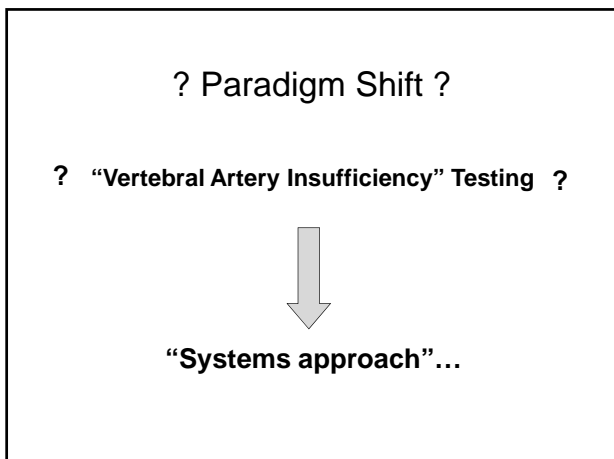
Cervical Arterial Dysfunction and Manual Therapy

UK position...

? Paradigm shift

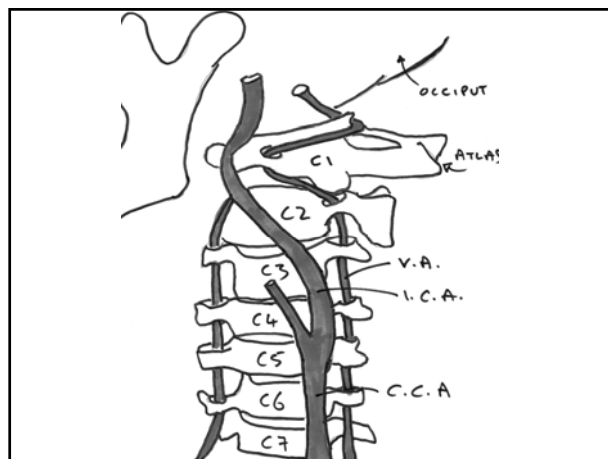


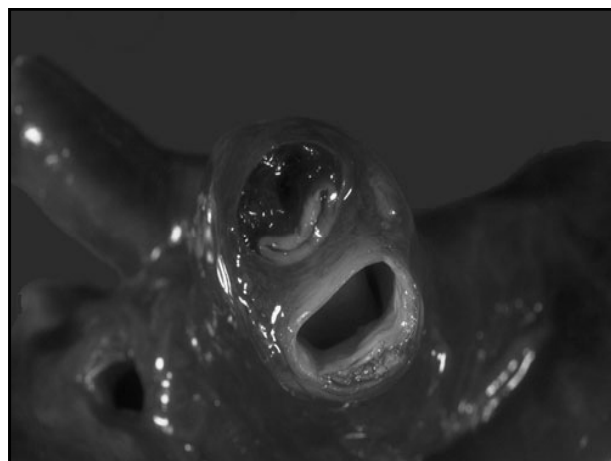
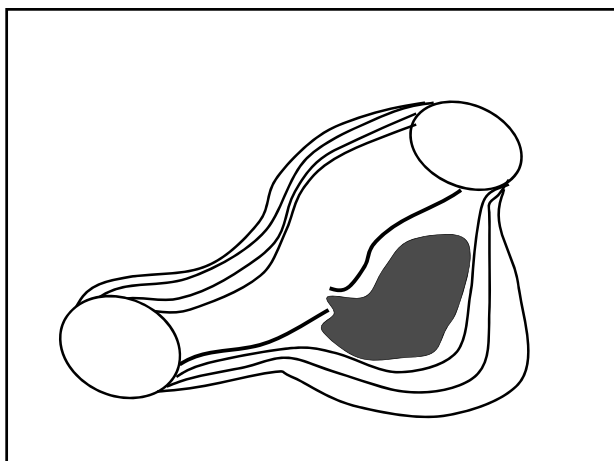
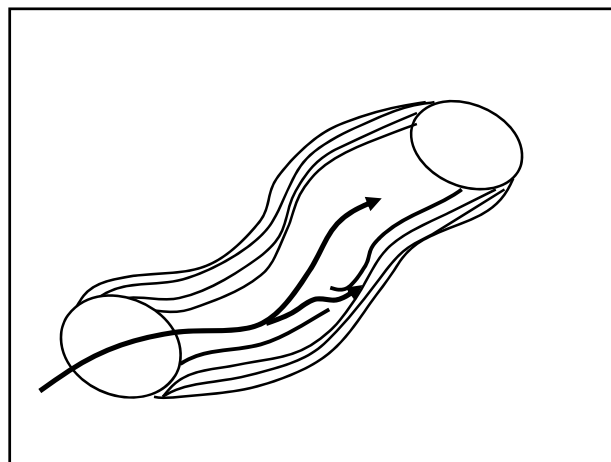
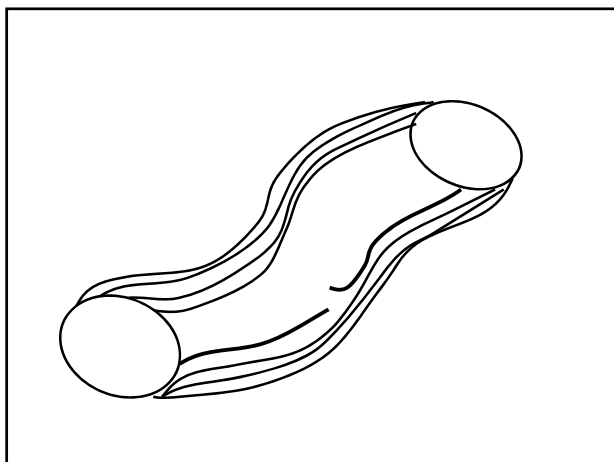

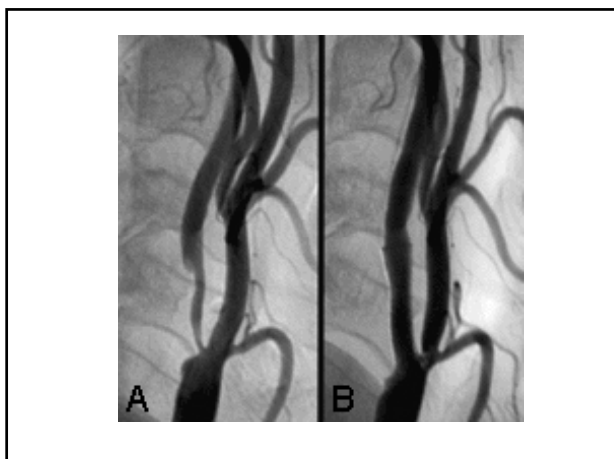
The diagram shows two triangles. A smaller triangle on the left is labeled 'VBI'. An arrow points from it to a larger triangle on the right labeled 'CAD'. Above the arrow is the text '? Paradigm shift'.

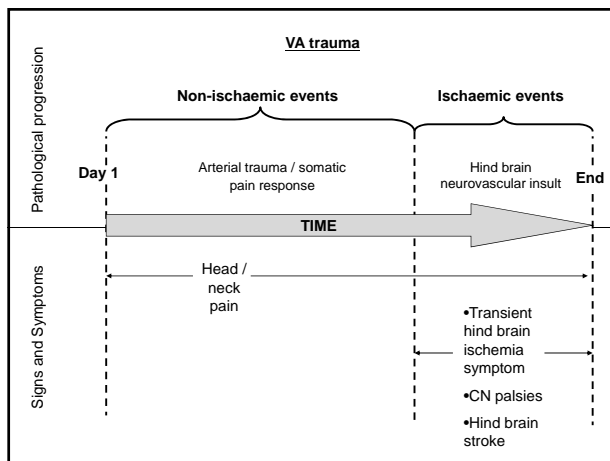
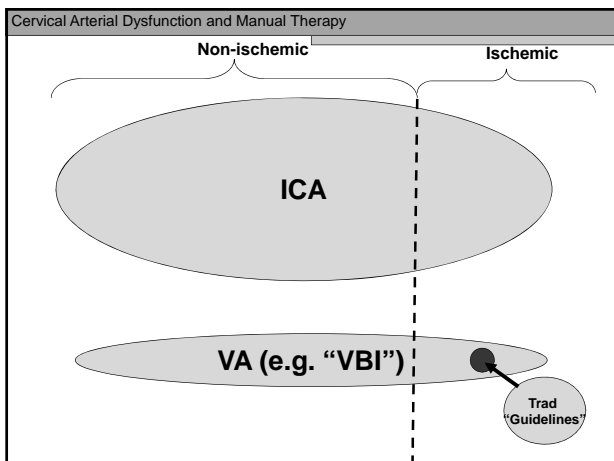
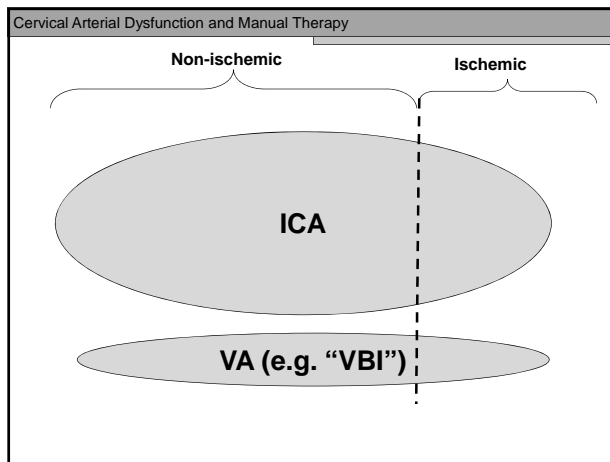
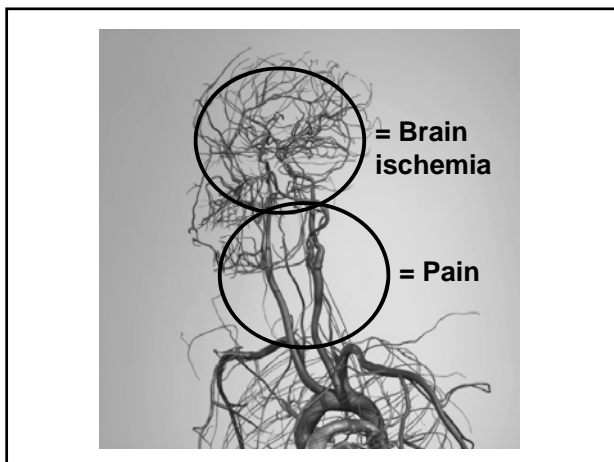
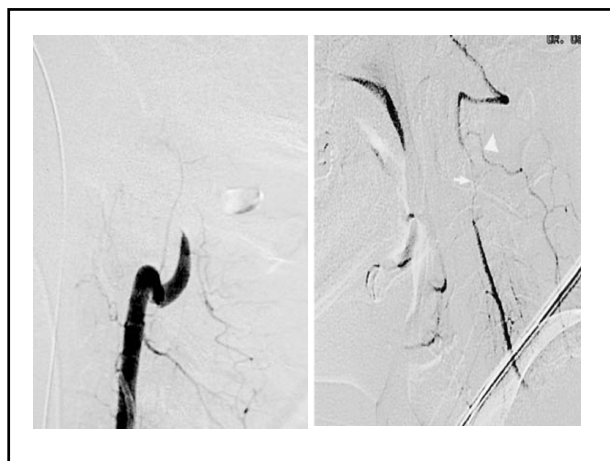
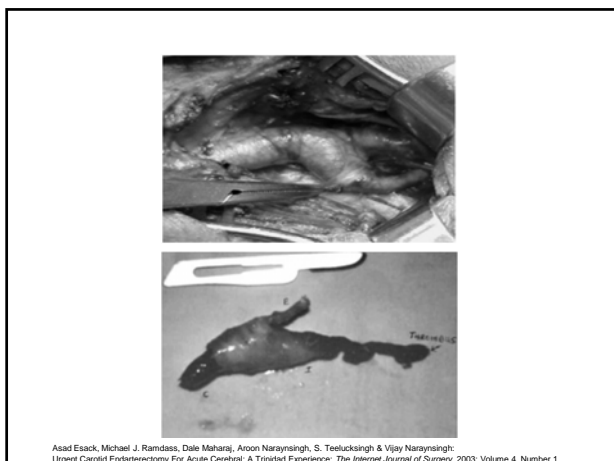


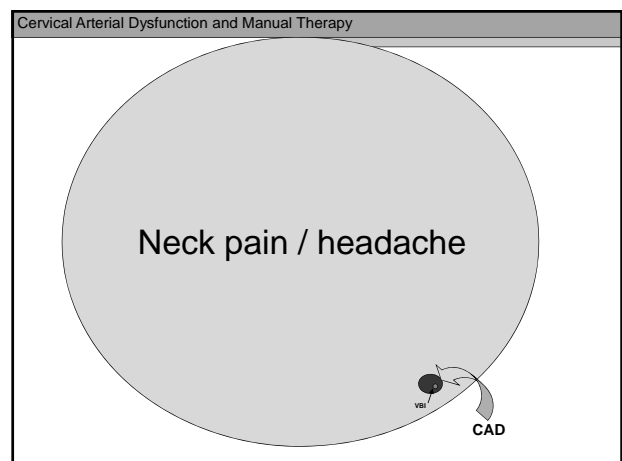
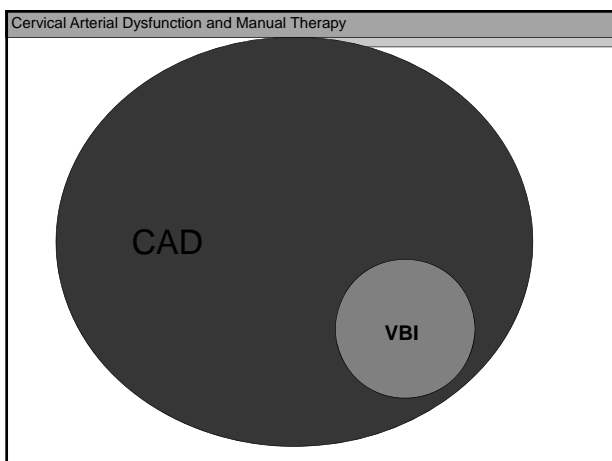
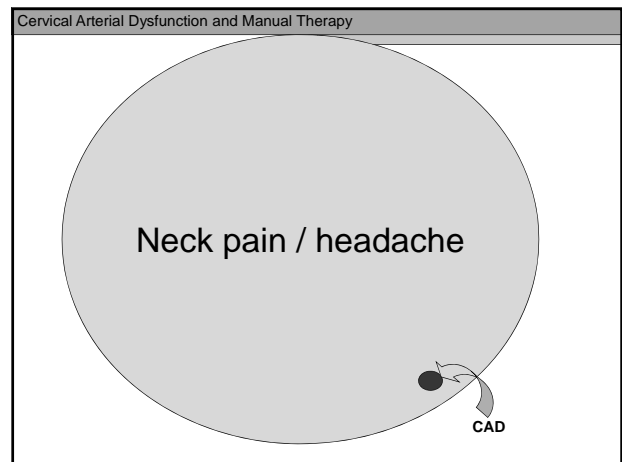
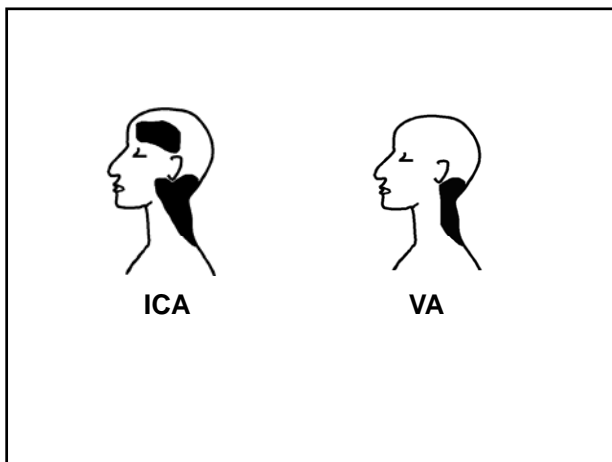
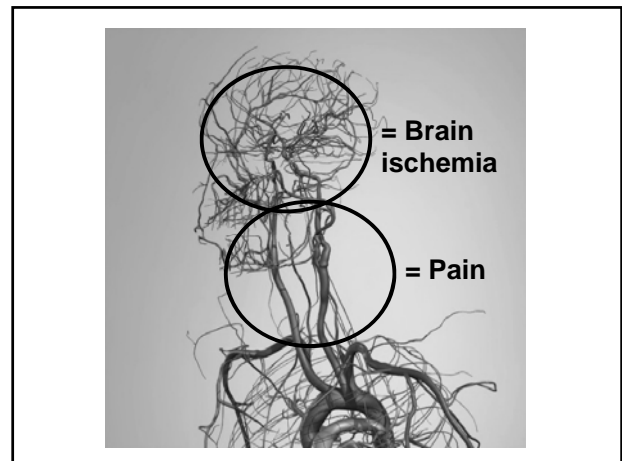
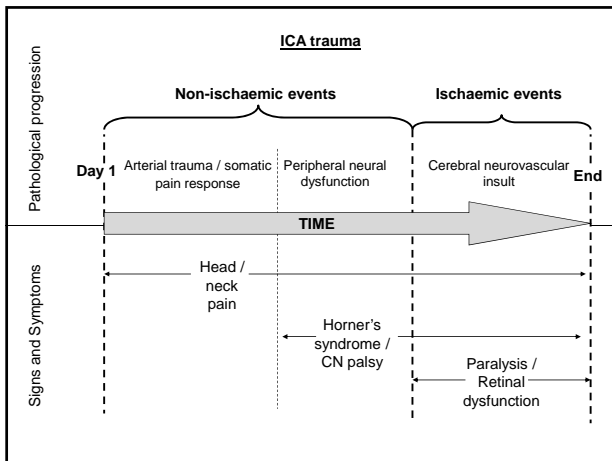
Cervical Arterial Dysfunction and Manual Therapy

Cervical Arterial Dysfunction – what is it?









Who?

Aarhus

These people...

Endothelial Dysfunction.

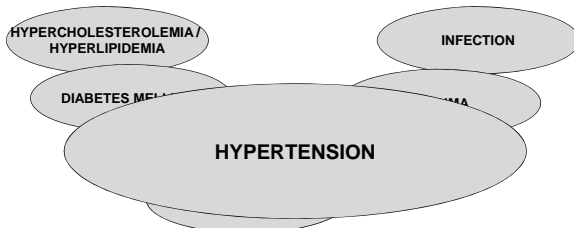
Risk factors for Endothelial Dysfunction



**ATHEROSCLEROSIS
RISK FACTORS**

ATHEROSCLEROSIS RISK FACTORS

↓
INFLAMMATORY PROCESS (ENDOTHELIAL DYSFUNCTION) INDUCED
BY CHEMICAL, MECHANICAL, OR IMMUNOLOGICAL INSULT



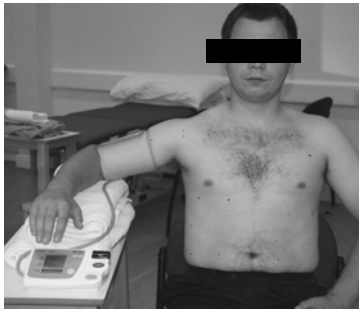Evaluation and Assessment

History

- Listen to patient! – NATURE OF PAIN!
- Consider previous neck trauma.
- Consider atherosclerosis / stroke risk factors.

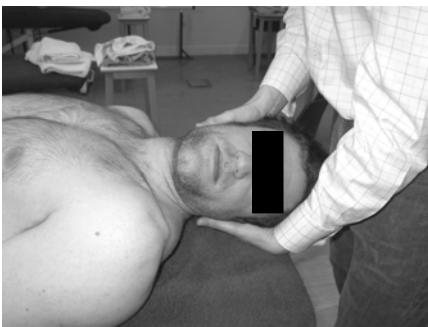
Physical examination

- Blood pressure



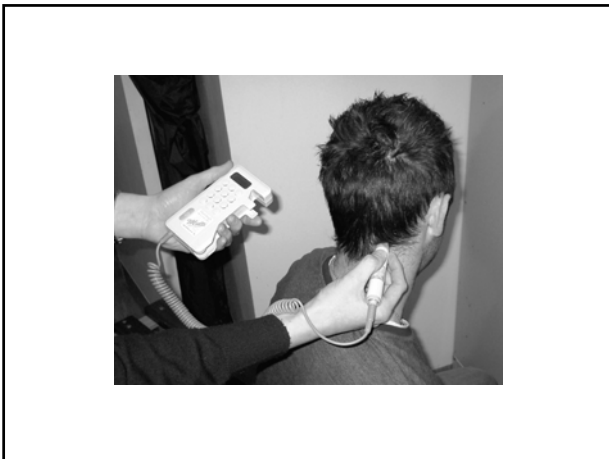
Physical examination

- Blood pressure
- Functional positional tests



Physical examination

- Blood pressure
- Functional positional tests
- Ultrasound Doppler



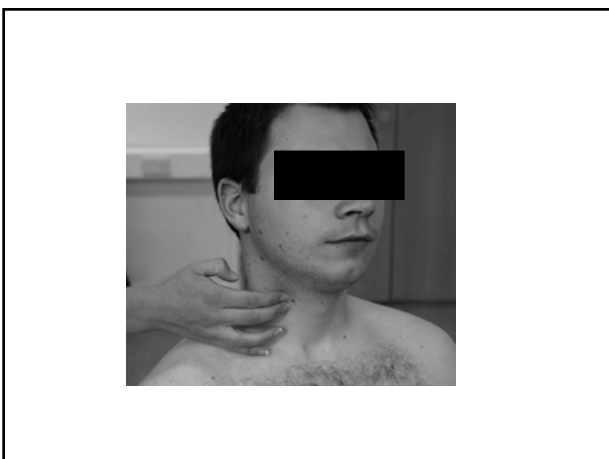Physical examination

- Blood pressure
- Functional positional tests
- US Doppler
- Cranial nerve examination



Physical examination

- Blood pressure
- Functional positional tests
- US Doppler
- Cranial nerve examination
- Pulse palpation




Physical examination


- Blood pressure
- Functional positional tests
- US Doppler
- Cranial nerve examination
- Pulse palpation
- Eye examination
- Proprioception tests (Romberg's; Tandem gait)

Cervical Arterial Dysfunction and Manual Therapy


Case Studies revisited



45-year-old male:
 - Headache +dizzy on lying down and rolling in bed;
 - Spinning of room last night for 10 seconds
 - Nausea++;
 - no other symptoms
 Health - fine




59-year-old male:
 - Headache, neck pain ("turning" 1/12
 - "Falling to side / up" without known cause
 - admitted to hospital and discharged after 1/7
 - dizziness resolved rapidly
 Health - O.B.G 2002




33-year-old female:
 Whiplash
 - Headache and neck pain with exacerbations;
 - Face pangs;
 - "Feeling in crowd"
 - "Feeling in gait"
 Health - fine

Fine: BPPV
Fine: VA dissection
Fine: WAD - SenMot

All "Simpsons" images: www.thesimpsons.com



42 year old male:
 - Neck pain (to jaw) / headache 1/12
 -History of migraines but not this type of pain before";
 -Thinks he has "muscle" in throat because has difficulty swallowing food/drink.
 - High BP; been doing "McKenzie" neck exercises - worsening.



72-year-old female:
 - Headache, neck pain, dizziness, unsteady, 'drunken' gait
 - Dizziness on quick head turning
 - Reduced hearing right ear
 - hypertension, hypercholesterolaemia

Refer: ICA dissection
Fine: SV disease + central vest


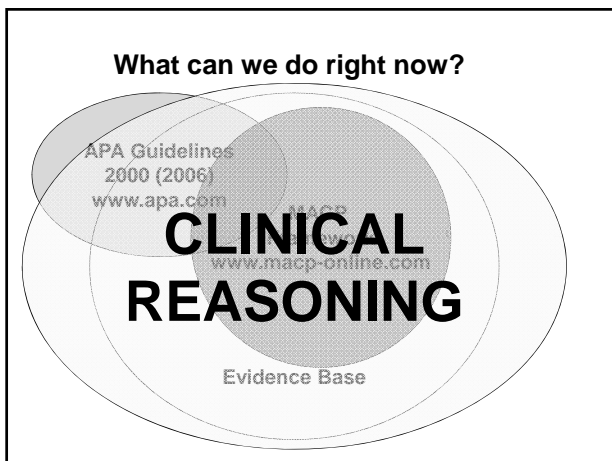
All "Simpsons" images: www.thesimpsons.com

Cervical Arterial Dysfunction and Manual Therapy

The State of The Science


- Uncertain
- Probability / Likelihoods
- Is clinically, individually meaningful
- Has clinical, individual magnitude

SHOULD NOT BE SIZELESS: " $p>0.05$ "!!!






JOSPT
Neck Special Edition May
2009
39(5)



MANIPULATING
ASSOCIATION OF
CHIROPRACTIC
PHYSIOTHERAPISTS




The University of
Nottingham

Cervical Arterial Dysfunction and Manipulative Therapy
INFORMATION DOCUMENT

www.macpweb.org

Roger Kerry, University of Nottingham, Nottingham, UK
Alan Taylor, Nottingham Nuffield Hospital, Nottingham, UK
Jeannette Mitchell, University of Wyoming, USA/University of West England, UK
Chris McCarthy, University of Warwick
John Brew, Keele University
Ruth Kiely, Physio4u, Galway, Republic of Ireland
Grahame Robertson, Whiston Hospital, Liverpool



Jan
2010!!

www.haemodynamics.com

www.heseminars.com



The University of
Nottingham

Thank you

The University of
Nottingham